

# Transtibial Osseointegration for Patients with Peripheral Vascular Disease

## A Case Series of 6 Patients with Minimum 3-Year Follow-up

Muhammad Adeel Akhtar, BSc, MBBS, MRCSEd, Dip SEM(UK), MD(Res), MFSEM, MFSTEd, PGDipCAOS, FEBOT, FRCSEd(T&O), Jason Shih Hoellwarth, MD, Shakib Al-Jawazneh, MD, William Lu, PhD, Claudia Roberts, BPhysio(Hons), and Munjed Al Muderis, MB, ChB, FRACS, FAOrthA

*Investigation performed at the Australian School of Advanced Medicine, Macquarie University, North Ryde, and the School of Medicine, The University of Notre Dame Australia, Auburn, New South Wales, Australia*

**Background:** The management of peripheral vascular disease (PVD) can require amputation. Osseointegration surgery is an emerging rehabilitation strategy for amputees. In this study, we report on 6 patients who had PVD requiring transtibial amputation (PVD-TTA) and either simultaneous or subsequent osseointegration (PVD-TTOI).

**Methods:** Six patients (aged 36 to 84 years) with transtibial amputation and preexisting PVD underwent osseointegration between 2014 and 2016 and were followed for 3 to 5 years. Pre- and postoperative clinical and functional outcomes (pain, prosthesis wear time, mobility, walking ability, and quality of life) and adverse events (infection, fracture, implant failure, revision surgery, additional amputation, and death) were prospectively recorded.

**Results:** All patients' mobility improved following osseointegration. Three patients initially had required the use of a wheelchair, precluding baseline walking tests; the other 3 were classified as K level 1 or 2, with mean baseline Timed Up and Go (TUG) test =  $14.0 \pm 2.2$  s and 6-Minute Walk Test (6MWT) =  $262 \pm 75$  m. At the time of the latest follow-up, all patients were K level 2 or 3; mean TUG =  $12.7 \pm 7.2$  s and 6MWT =  $353 \pm 148$  m. Four patients wore their prosthesis  $\geq 16$  hours daily. Three patients had superficial soft-tissue infections. One other patient experienced recurrent infections 2.8 years after osseointegration requiring debridements and transfemoral amputation; the patient died 2 days following surgery from myocardial infarction caused by coronary atherosclerosis.

**Conclusions:** All 6 patients who underwent PVD-TTOI in this case series survived through 2 years. Patients who initially had used a wheelchair achieved and maintained independent, unaided ambulation until PVD-related impairments in the contralateral leg occurred in 1 patient. Patients previously using a traditional socket prosthesis reported improvement in mobility and quality of life. One patient's death underscores the importance of careful patient selection. However, marked improvement in the other 5 patients suggests cautious optimism that PVD-TTA is not an absolute osseointegration contraindication. Conscientious further investigation seems appropriate.

**Level of Evidence:** Therapeutic Level IV. See Instructions for Authors for a complete description of levels of evidence.

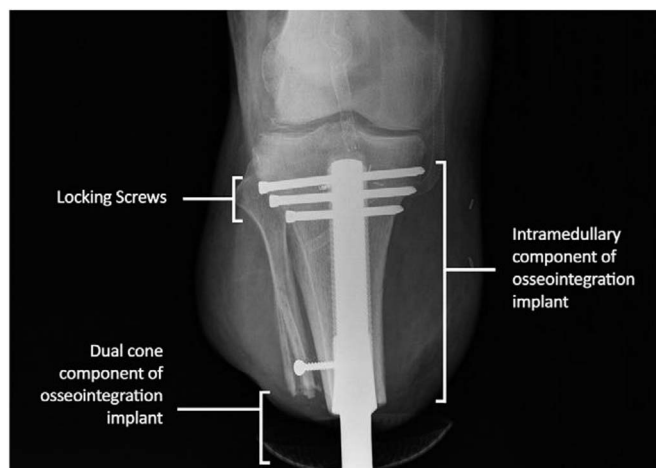
Peripheral vascular disease (PVD) is the leading cause of lower-limb amputation in developed countries<sup>1-4</sup> and is associated with high morbidity and mortality, particularly in elderly patients<sup>5-8</sup>. The rates of mortality after major amputation have been reported to be 44%, 66%, and 85% after 1, 3, and 5 years, respectively<sup>9,10</sup>. The high rate of 1-year mortality is usually from associated stroke or myocardial infarction (MI)<sup>11-15</sup>. Studies investigating health-related quality of life (QoL) in patients with PVD have revealed that QoL is primarily determined by

mobility impairment<sup>16,17</sup>. Therefore, restoring functional mobility may provide substantial benefit to these amputees<sup>18</sup>. Unfortunately, patients with PVD requiring transtibial amputation (PVD-TTA) often also have lower-limb skin compromise, neuropathy, and visual and vestibular pathology, which further impair mobilization with a traditional socket prosthesis.

Osseointegration surgery has revolutionized amputee rehabilitation by eliminating socket-interface problems<sup>18-20</sup>. Osseointegration is performed predominantly for transfemoral amputees<sup>21-25</sup>,

**Disclosure:** The **Disclosure of Potential Conflicts of Interest** forms are provided with the online version of the article (<http://links.lww.com/JBJSOA/A285>).

Copyright © 2021 The Authors. Published by The Journal of Bone and Joint Surgery, Incorporated. All rights reserved. This is an open-access article distributed under the terms of the [Creative Commons Attribution-Non Commercial-No Derivatives License 4.0](https://creativecommons.org/licenses/by-nc-nd/4.0/) (CCBY-NC-ND), where it is permissible to download and share the work provided it is properly cited. The work cannot be changed in any way or used commercially without permission from the journal.



**Fig. 1**  
Radiograph representative of the press-fit osseointegration implant in the tibial residuum of a patient who became a transtibial amputee due to vascular disease complications.

consistently improving prosthetic use, proximal joint range of motion, mobility level, walking ability, and QoL, and reducing energy consumption<sup>26-29</sup> compared with traditional socket prosthesis. Traditionally, PVD-TTA contraindicates osseointegration<sup>26,27,30</sup>. To investigate this reservation, a previously published pilot study reported the 1-year outcomes of 4 patients with PVD-TTA managed with osseointegration (PVD-TTOI)<sup>31</sup>. In this study, we further evaluated the experience of those 4 patients and 2 additional patients (6 patients total), who were followed for 3 to 5 years.

**Materials and Methods**

*Study Design*

This was a consecutive case series of 6 patients prospectively followed for 3 to 5 years. Clinical outcomes, functional outcomes, and adverse events were monitored and evaluated. The general study design was recently published<sup>32</sup>. The senior author performed all surgical procedures and followed all patients in entirety.

*Participants*

All patients had PVD-TTOI between September 2014 and June 2016, in Sydney, New South Wales, Australia. Inclusion criteria were an age of ≥18 years and unilateral transtibial amputation due to PVD complications. Exclusion criteria included psychological instability, limb irradiation, and ongoing chemotherapy. Human research ethics committee approval was received, and all participants provided informed consent.

*Preoperative Counseling*

All patients were informed of the risks and benefits of osseointegration. The patients who had already undergone transtibial amputation had problems that are common with use of a traditional socket prosthesis following transtibial amputation: painful prosthesis wear, skin breakdown, and/or the inability to wear a prosthesis due to short residuum. These patients desired consistently better mobility. Patients presenting prior to amputation wanted to avoid the aforementioned problems, which they were counseled about by their initial consulting surgeons. Both groups were counseled by other surgeons, and by us, that the traditional

**TABLE I Patient Demographic Information and Reasons for Osseointegration Surgery**

Case	Sex	Age (yr)	Time from Amputation to Osseointegration Surgery (yr)	Preop. Tibial Length (cm)	Reason for Osseointegration Surgery
1	M	76	0	14.85	Osseointegration performed to salvage the knee joint as an alternative to above-the-knee amputation. Socket fitting on the tibia was difficult due to soft-tissue conditions
2	F	66	13	14.22	Excessive phantom limb pain and socket-interface problems. Surgical removal of neuroma and bone spur failed to resolve the problem
3	M	84	0	15.85	Osseointegration performed to salvage the knee joint as an alternative to above-the-knee amputation. Socket fitting on the tibia was difficult due to soft-tissue conditions
4	F	56	4	9.47	Excessive phantom limb pain and socket-interface problems. Multiple stump revisions were attempted without positive results
5	M	36	7	11.1	Osseointegration performed to address overall decline in function and QoL due to socket-interface problems in the form of changing size of the stump, a large amount of redundant tissue, unbearable pain associated with rubbing, chafing, and blistering around the socket on using the prosthesis for long walks, and an allergy to the liners resulting in poor socket fit
6	M	67	0	16	Osseointegration performed to address ongoing ischemia in the left lower limb with nonhealing ulcers on the foot and dry gangrene of the left great toe, ischemic pain at rest, and claudication on mobilizing >20 ft (6 m) despite multiple revascularization procedures

TABLE II Medical History and Postoperative Clinical Outcomes for Each Case at 12 Months and Latest Follow-up

Case	Preop. Medical History	Outcome at 12 Mo	Outcome at Latest Follow-up
1	Popliteal artery thrombosis treated with femoral-popliteal bypass. Bypass failed, leading to compartment syndrome with necrosis. Multiple vascular ops. afterward	Able to walk unaided with osseointegrated prosthesis; no pain, no infection events to date	Able to walk unaided with osseointegrated prosthesis; no pain, no infection events to date. The left tibial stump has a small area of exposed tibia that was not causing any problems. Radiographs show good alignment and integration of transtibial osseointegrated implant
2	Amputation originally caused by motor-vehicle accident, after which the patient used a socket. The patient was later diagnosed with Wegener vasculitis; controlled with prednisone	Able to walk unaided with osseointegrated prosthesis; no pain, minor infection treated with oral antibiotics	Able to walk unaided with osseointegrated prosthesis; had pain and moderate discharge. Radiographs showed good alignment and integration of implant. Minor infection treated with oral antibiotics
3	Femoral-popliteal bypass that failed due to thrombosis, leading to transtibial amputation	Able to walk unaided with osseointegrated prosthesis; no pain, no infection events to date	Living alone at home and able to perform activities of daily living alone. Able to walk on the leg with a front-wheeled walker frame and prosthesis. On examination, the stump appeared healthy. The patient did not report infection but had chronic pain (not related to osseointegration) and poor mobility due to vascular surgery in May 2019 (bypass graft, contralateral leg, for aneurysm). Radiographs showed good osseointegration to the tibia
4	Femoral-popliteal bypass that failed due to thrombosis, leading to multiple salvage operations and finally transtibial amputation	Able to walk unaided with osseointegrated prosthesis; no pain, minor infection treated with oral antibiotics.	Patient had 2 debridements for deep infection in January and October 2017 along with antibiotic therapy. After the second washout in November 2017, she was unable to walk because of leg pain and had persistent discharge from the stoma. She was systemically well, and pathology report showed that the stoma was colonized with <i>Pseudomonas</i> , which was resistant to ciprofloxacin. She was admitted for removal of the transtibial osseointegrated implant and had above-knee amputation due to recurrent infection in early 2018, and died 2 days following surgery. Her medical history included diabetes mellitus, hypertension, hypothyroidism due to Hashimoto disease, morbid obesity (body mass index of 41.4 kg/m <sup>2</sup> ), and 15-pack-yr smoking history.  Postmortem identified the cause of death as acute MI due to coronary atherosclerosis
5	Right below-knee amputation 7 yr earlier, after failed femoral-popliteal bypass for ischemic episodes due to Berger syndrome (microvascular disease) and poor compliance (heavy tobacco and marijuana use)	Able to walk unaided with osseointegrated prosthesis; no pain, minor infection with <i>Staphylococcus aureus</i> treated with oral antibiotics in July 2016	Able to walk unaided with osseointegrated prosthesis; no pain but had discharge. Minor infection treated with oral antibiotics  Minimal oozing from stoma thought to be due to mechanical issue, as the patient was very active and was treated with dual cone exchange in the clinic

continued

TABLE II (continued)

Case	Preop. Medical History	Outcome at 12 Mo	Outcome at Latest Follow-up
6	Multiple failed revisualization procedures. Femoral-popliteal bypass in 1994 and revision in February 2016. Patient sustained a work-related injury 22 yr ago resulting in bilateral knee dislocation with vascular injuries and left foot drop	Able to walk unaided and play golf with osseointegrated prosthesis; no pain, minor infection with <i>S. aureus</i> treated with oral antibiotics in November 2017	Able to walk unaided around the golf course and play golf with osseointegrated prosthesis; no pain, no infection, minimal discharge

management for the inability to tolerate a transtibial traditional socket prosthesis is a transfemoral amputation (TFA), which hopefully provides better soft-tissue coverage and extremity length for a new femoral-level traditional socket prosthesis. However, adults with PVD often have unfavorable body habitus and physical deconditioning. Additionally, losing the knee joint would demand substantially greater ambulation effort, which might still result in unsuitable mobility despite the amputation. A TTOI prosthesis would preserve their knee joint, facilitating lower-energy ambulation, and eliminate socket-based issues. Patients were informed that relatively few people had ever had TTOI, and they would be among the first with PVD to have osseointegration. Therefore, outcomes could not be confidently predicted. Although no patient required a proximal-level amputation or died due to osseointegration-related complications, the risk of potential infection with osseointegration versus a traditional socket prosthesis is increased due to the open stoma, and PVD likely confers additional risk versus that for patients without PVD who have osseointegration. Should TTOI not provide appropriate mobility or result in complications, transfemoral amputation could always be performed. Presented with these risks and benefits, each patient elected for TTOI.

### Surgery and Rehabilitation

Prior to surgery, imaging according to the Osseointegration Group of Australia Accelerated Protocol-2 (OGAAP-2) was obtained to produce custom implants<sup>33</sup>. Two operative techniques were utilized. For 3 patients who already had transtibial amputation, a coring device allowed percutaneous access to the distal part of the tibia with minimal soft-tissue disruption. Osseous fibrous overgrowth was excised, reaming was performed over a guidewire, and the press-fit implant was inserted. For the 3 patients undergoing primary amputation with osseointegration, amputation was performed preserving a large tissue flap. The residual bone canal was reamed and a press-fit implant was inserted. In 5 patients, cross-lock screws were inserted into customized holes to ensure rotational stability (Fig. 1); 1 patient had no supplemental fixation. The external dual cone and prosthesis adaptor were attached during surgery.

The previously published postoperative care and rehabilitation protocols were followed<sup>34,35</sup>, summarized as (1) progressively increasing static axial loading within 3 days after

osseointegration surgery, (2) advancing axial loading with use of a light rehabilitation prosthesis, and (3) full-weight axial loading with a personalized prosthesis at 4 to 6 weeks post-operatively. No casts or splints were used.

### Study Outcomes

#### Functional Outcomes

Functional outcomes were assessed preoperatively, at 12 months, and at the most recent visit. Patient self-reported QoL was measured using the Short Form (SF)-36 mental and physical component summary scores. Hours of daily prosthesis wear were assessed using the Questionnaire for Persons with a Transfemoral Amputation (Q-TFA), modified for transtibial amputees<sup>36</sup>. The principal investigator determined mobility capacity according to K levels (K0 through K4; K0 identifies patients with no ambulatory potential or ability, whereas K4 identifies patients with ambulatory capacity or potential exceeding basic ambulatory skills<sup>37</sup>). The 6-Minute Walk Test (6MWT)<sup>38</sup> and the Timed Up and Go (TUG) test<sup>39</sup> quantified walking performance.

#### Adverse Events

Adverse events, such as revision surgery, fracture, infection, implant failure, further vascular surgery, additional amputation, and death, were reported.

#### Data Analysis

Because of the small cohort, only descriptive statistics (without comparative statistics) are presented.

#### Source of Funding

There were no sources of funding for this study.

## Results

### Patient Characteristics

Six patients (4 male, 2 female) who were 36 to 84 years of age were included (Table I). The medical history and outcomes of each patient are summarized in Table II. All patients had transtibial amputation due to peripheral vascular pathology.

Three patients (Cases 1, 3, and 6) had primary amputation with osseointegration to manage femoral-popliteal bypass surgery that failed, causing compartment syndrome with necrosis in 1 (Case 1) and graft thrombosis in 2 patients (Cases 3 and 6). All were elderly (76, 84, and 67 years of age, respectively) with fragile skin providing minimal soft tissue,

TABLE III Outcome Measures for Each Patient\*

Case	Prosthetic Use		Mobility ( <i>K Level</i> )	Walking Ability		Quality of Life		
	Using Prosthesis	Q-TFA PUS		6MWT ( <i>m</i> )	TUG ( <i>sec</i> )	SF-36 PCS	SF-36 MCS	Q-TFA GS
Baseline								
1	No	WB	0	WB	WB	22.2	32.8	WB
2	Yes	90	1	175	16.47	20.1	60.7	41.7
3	No	WB	0	WB	WB	16.6	68.3	WB
4	No	WB	0	WB	WB	32.6	51.1	WB
5	Yes	90.32	2	300	12.86	41.8	64.0	50
6	Yes	NA	2	312	12.47	34.7	35.9	NA
12-mo postop.								
1	Yes	32	2	300	9.61	40.1	41.2	58.3
2	Yes	90	3	406	8.59	38.9	62.2	58.3
3	Yes	100	2	144	26.08	38.9	70.3	83.3
4	Yes	90	2	275	12.69	44.4	53.3	58.3
5	Yes	100	3	375	7.23	38.8	47.6	58.3
6	Yes	100	3	550	10.3	53.0	46.6	58.3
Difference between baseline and 12-mo follow-up								
1		—	2	—	—	17.9	8.4	—
2		0	2	231	-7.88	18.8	1.5	16.6
3		—	2	—	—	22.3	2.0	—
4		—	2	—	—	11.8	2.2	—
5		9.68	1	75	-5.63	-3.0	-16.4	8.3
6		NA	1	238	-2.17	18.3	10.7	NA
Latest follow-up†								
1	Yes	100	2	306.2	12.38	45.89	60.53	66.67
2	Yes	90.32	3	412.5	9.09	46.11	59.72	75
3	Yes	100	2	87.5	27	50.21	55.73	66.67
4	Yes	70.97	—	375	10.6	41.38	38.70	58.33
5	Yes	100	3	412	8.73	42.0	40.3	50
6	Yes	100	3	525	8.38	58.7	54.6	75
Difference between baseline and latest follow-up								
1		—	2	—	—	23.69	27.73	—
2		0.32	2	237.5	-7.38	26.01	-0.98	33.3
3		—	2	—	—	33.61	-12.57	—
4		—	—	—	—	8.78	-12.4	—
5		9.68	1	112	-4.13	0.2	-23.7	0
6		NA	1	213	-4.09	24	18.7	NA

\*WB = wheelchair-bound at the time of examination so the test could not be performed, Q-TFA = Questionnaire for Persons with a Transfemoral Amputation, PUS = Prosthetic Use Score (defined as the amount of normal prosthetic wear per week, with a score of 100 indicating that the prosthesis was worn every day for  $\geq 16$  hours a day), GS = global score (defining the overall amputation situation, including function and problems, with a score of 100 indicating the best possible overall situation), 6MWT = 6-Minute Walk Test (distance in meters that an individual was able to walk in 6 minutes), TUG = Timed Up and Go (time in seconds that an individual required to rise from a chair, walk 3 m, return, and sit down), SF-36 = Short Form-36 Health Survey, PCS = physical component summary score, MCS = mental component summary score, and NA = not available. †One patient (Case 4) died 2.8 years following the osseointegration surgery.

making the fitting of a tibial traditional socket prosthesis problematic. A transtibial amputation with simultaneous osseointegration was performed in order to preserve the knee joint.

The 3 remaining patients (Cases 2, 4, and 5) had amputation several years preceding osseointegration. All of these patients struggled with traditional socket prosthesis use, reporting intolerable socket-interface problems.

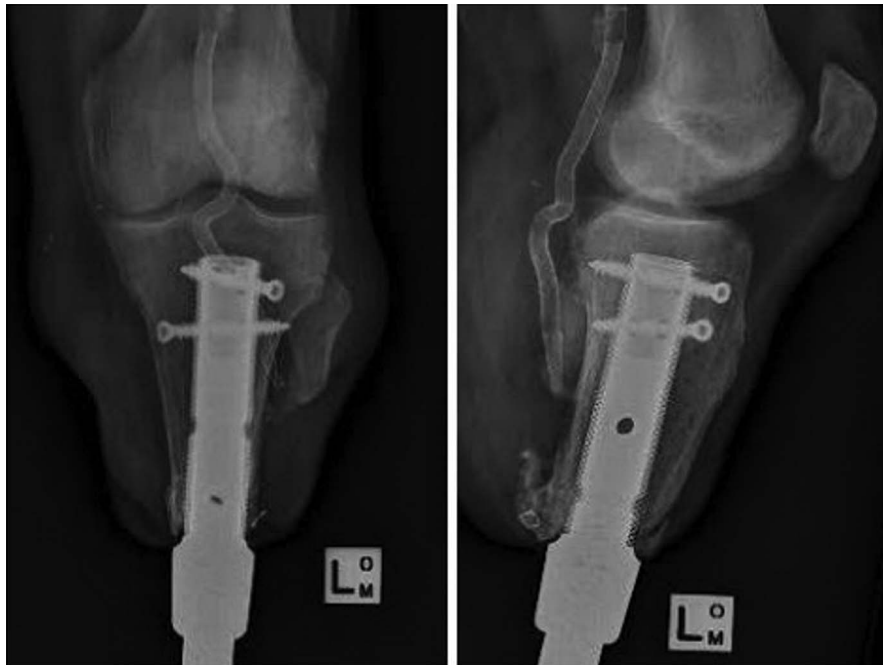

Fig. 2-A

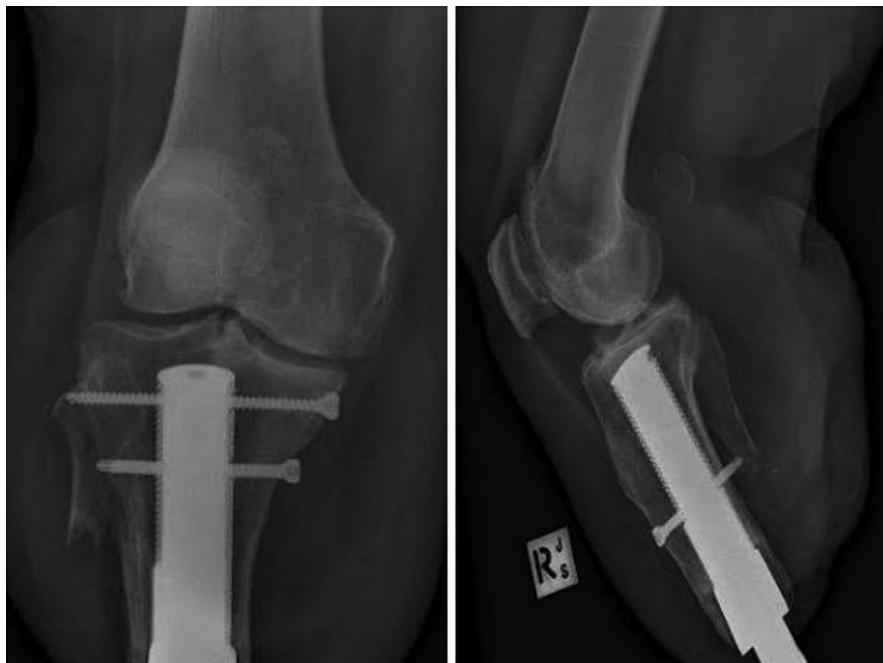

Fig. 2-B

**Figs. 2-A through 2-F** Most recent radiographs of the limbs of Cases 1 to 6.

### *Clinical Outcomes*

All patients progressed in weight-bearing and mobilization as per the protocol<sup>34,35</sup>. At the latest postoperative follow-up evaluation, all 5 of the patients who were still alive could walk using the osseointegrated prosthesis (4 unaided and 1 using a front-wheeled walker because of contralateral vascular impairment). Four patients reported no pain at 5 years following

osseointegration, and 1 of these patients was planning vascular surgery for the contralateral leg.

### *Functional Outcomes*

Before osseointegration, 3 patients (Cases 1, 3, and 4) needed to use a wheelchair. At 12 months postoperatively, all 6 patients walked unaided using their osseointegrated prosthesis. At the

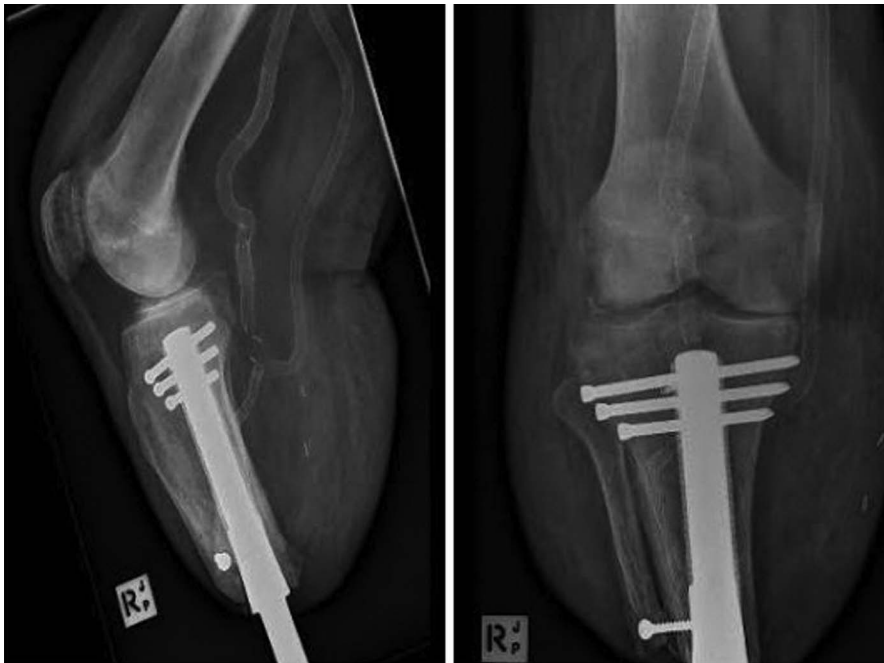

Fig. 2-C

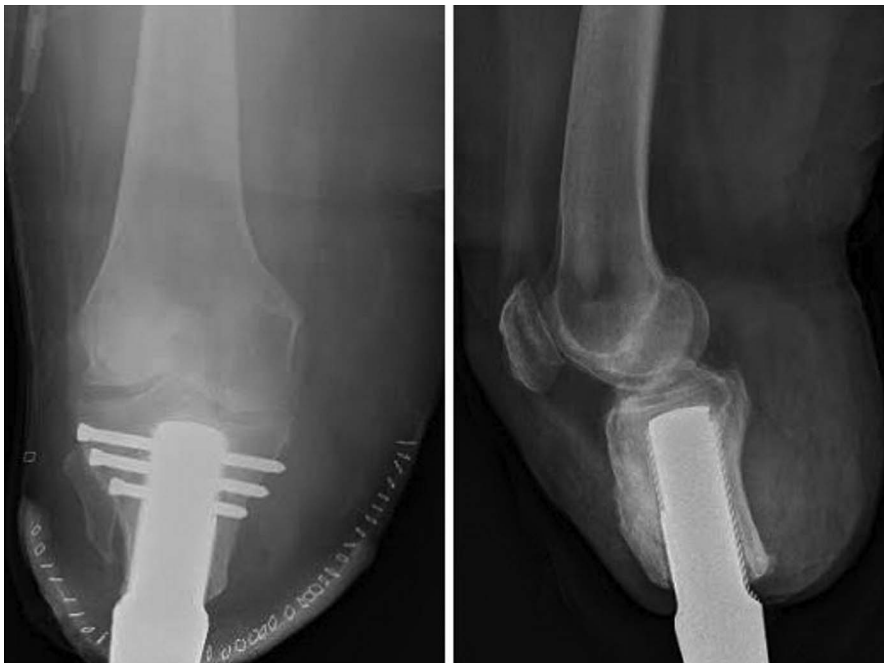

Fig. 2-D

time of the most recent follow-up, all 5 patients who were alive were independently mobile. Each patient's functional and QoL scores are presented in Table III. At 1 year, better TUG and 6MWT results were noted for the 3 originally ambulatory patients. The 3 patients who initially had used a wheelchair all performed walking tests after surgery, achieving TUG results of 9.61 to 26.08 seconds and 6MWT results of 144 to 300 m. The SF-36 physical component summary score was a mean of 42.35 at 12 months and had improved from baseline by a mean of

14.35 points for all patients, while the average SF-36 mental component summary score remained stable.

Functional outcome measures at the latest follow-up are shown in Table III. All patients' K levels<sup>37</sup> progressed 1 or 2 levels from baseline. The 3 patients who were ambulatory at baseline had improved at latest follow-up, by 7.38, 4.13, and 4.09 seconds for the TUG and 237, 112, and 213 m for the 6MWT. Three previously nonambulatory patients achieved results of 12.38, 27, and 10.6 seconds for the TUG and 306, 87.5, and 375 m for the



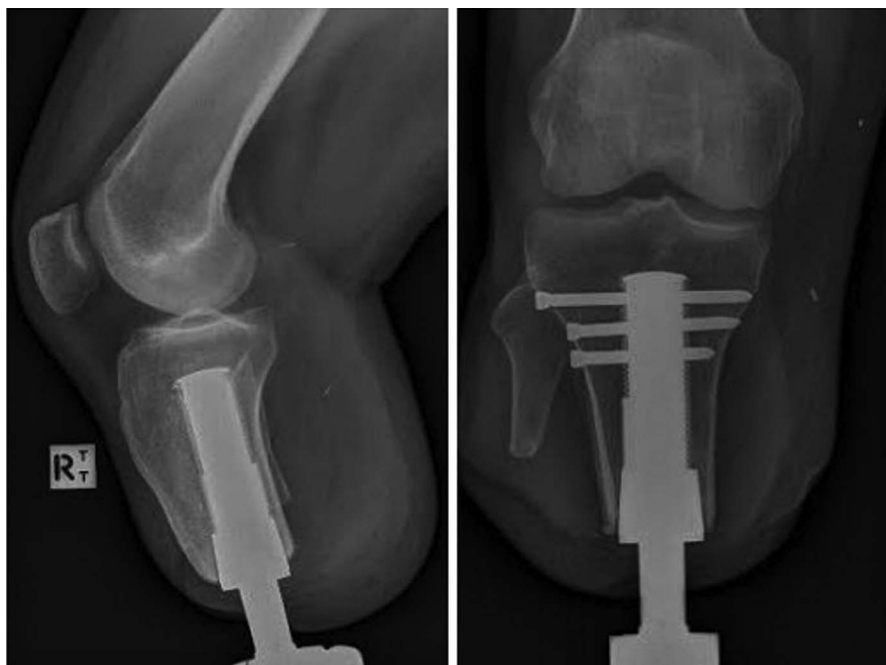

Fig. 2-E

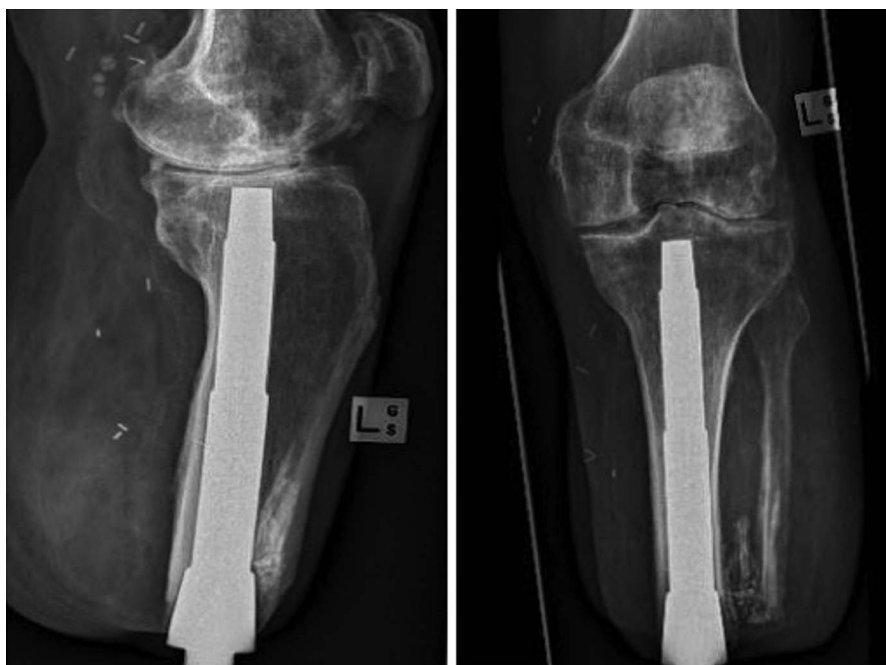

Fig. 2-F

6MWT. The SF-36 physical component summary score was a mean of 47.38 at latest follow-up and had improved from baseline by a mean of 19.38 points, while the average mental score component summary score again stayed stable.

All radiographs demonstrated that implants remained well aligned and stable. Immediate and final postoperative radiographs indicated bone-implant osseointegration without loosening, osteitis, or resorption (Figs. 2-A through 2-F). At final evaluation, stoma healing was complete with mini-

mal discharge; there was no notable granulation or stoma irritation.

#### *Adverse Events*

One patient (Case 1) developed a small area of exposed tibia near the stump (Fig. 3), which had yet to cause any problems 5 years after osseointegration (Video 1). One patient (Case 3) had persistent bilateral claudication requiring use of a front-wheeled walker for ambulatory assistance; he eventually had



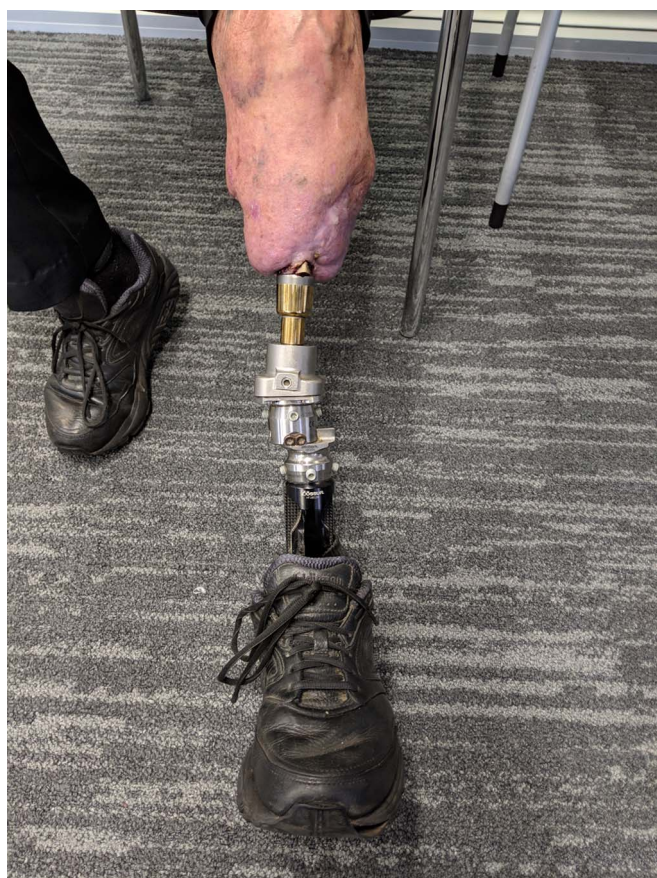

Fig. 3  
A clinical photograph of the stump with exposed tibia (Case 1) and artificial limb attached.

contralateral popliteal bypass grafting. Three patients had superficial soft-tissue infections, which were treated with 2 courses of oral antibiotics in 2 cases (Cases 2 and 5) and 1 course of oral antibiotics in the remaining case (Case 6).

One patient (Case 4) with notable medical comorbidities developed deep infection 2.8 years following osseointegration surgery, which was unable to be controlled despite 2 debridements. To control the infection, transfemoral amputation was performed. Unfortunately, the patient died 2 days later. A postmortem evaluation identified the cause of death as acute MI due to severe coronary atherosclerosis.

## Discussion

The most important insight from our study is that vascular disease, in itself, is not an absolute contraindication to TTOI. Through 2 years, all 6 patients were alive; 5 were independently mobile without additional surgery, and 1 required a front-wheeled walker because of PVD problems in the contralateral leg. All 3 patients who initially required the use of a wheelchair achieved and maintained painless, independent ambulation, and all 3 patients with dissatisfaction with a traditional socket prosthesis improved their QoL and objective mobility measures. One patient with substantial systemic comorbidities developed

unrelenting infection nearly 3 years after osseointegration surgery and died of MI shortly after transfemoral amputation. Her preoperative consultations emphasized her elevated risk due to multiple comorbidities; she acknowledged these risks and requested osseointegration, achieving 2.8 years of pain- and complication-free ambulation.

No implants became loose or painful—including in the patients who developed infection—suggesting that successful bone-implant integration occurred and was maintained. The small patient sample precludes formally comparing the patients with prior amputation with those having simultaneous amputation with osseointegration. All final K levels were 2 or 3; those with prior amputation had a mean (and standard deviation) 6MWT result of  $400 \pm 21.5$  m, compared with  $306 \pm 219$  m for those who underwent amputation with simultaneous osseointegration.

Mortality rates for patients with vascular disease remain high following major lower-extremity amputation: 14%, 48%, and 71% at 30 days, 1 year, and 3 years, respectively<sup>9,12-14</sup>. This is often because of major associated systemic complications, such as cerebral or cardiac injury, sometimes present at amputation, sometimes developing afterward. Physical activity appears to reduce vascular risk factors, proportional to the metabolic equivalent task (MET)<sup>40</sup>. Even low-MET physical tasks, such as walking or leisure-time activity, are correlated with a decreased rate of coronary events and ischemic stroke<sup>41-44</sup>, which are the major determinants of acute deterioration leading to death for patients who undergo PVD-TTA. A review of osseointegration outcomes identified that, compared with use of a traditional socket prosthesis, osseointegrated reconstruction is consistently associated with more hours of daily prosthesis wear and a lower energy requirement for ambulation<sup>26</sup>, and easier short mobility tasks (TUG) and longer-distance mobility (6MWT)<sup>45</sup>. Therefore, it is possible that, for appropriately selected patients, TTOI may indirectly optimize survival-improving mobility. With only 6 patients in the current study, we cannot provide insight regarding that potential.

Osseointegration is most commonly performed for transfemoral amputees with nonvascular amputation etiology (mostly for the inability to reconstruct an extremity following trauma), and thus, most studies evaluate those patients' outcomes<sup>21,24-30,44</sup>. However, to our knowledge, there are only 5 published TTOI studies, reporting on 3 cohorts of 22 total patients, including 4 patients in the current study who were also in our pilot study of early outcomes<sup>31</sup>. In 2015, Khemka et al.<sup>44</sup> reported on 4 patients with TTOI connected to a total knee replacement who were followed for 12 to 32 months; all patients reported no pain and further procedures were not needed. Writing about the same 9 patients who were followed for an unspecified time, Juhnke and Aschoff<sup>26</sup>, Aschoff and Juhnke<sup>47</sup>, and Hoffmeister et al.<sup>48</sup> reported that 3 implants were removed: 2 for infection and 1 for aseptic loosening. In 2019, Leijendekkers et al.<sup>49</sup> reported that, at 1 year, 9 patients with TTOI reported improved pain, and at least 1 patient had explanation for infection. Apart from our patient with numerous comorbidities, our 5 other patients' outcomes compare well with the previously reported patients' experiences.

There are several reasons that TTOI is performed far less often than transfemoral osseointegration (TFOI). One reason is the geometric challenges of TTOI versus TFOI. Briefly summarized, since the tibia is nearly perfectly straight in coronal and sagittal planes, and has a proximal metaphyseal flare, it is more difficult to achieve press-fit stability compared with the curved femur. Indeed, rotational stability concerns were what prompted cross-screw customization in 5 of our patients. The effect of this supplemental fixation can only be appropriately assessed with larger cohorts. No TTOI reports could be found for the screw-style Osseointegrated Protheses for the Rehabilitation of Amputees (OPRA, Integrum) or the Compress (Zimmer Biomet), which features rotational stability pins. These implants' inherent designs might be beneficial regarding the tibia's geometry. Another reason for less TTOI interest is because those with transtibial amputation generally have better objective mobility than those with transfemoral amputation<sup>50,51</sup>, leading some clinicians to believe that there is no room for improvement by providing TTOI. We disagree with that position. Although transtibial amputations generally have better objective mobility than transfemoral amputations, QoL outcomes are similar. Amputee QoL is not substantially influenced by amputation level, but instead, is likely more influenced by depression, functional mobility, and other social and overall health factors<sup>52</sup>. Since much of any amputee's frustration includes socket issues, osseointegration may offer a unique advantage. In this study, the average SF-36 physical component summary score improved by 19.38 from baseline to the latest follow-up, while the mean SF-36 mental component summary score remained stable. The objective mobility improved for all patients. When considered in full, this can serve as a reminder that major systemic health problems such as PVD can overwhelm the benefits of physical improvement. It is also interesting that the average SF-36 physical component score improvement at 1 year in our study (14.35 points) was greater than that reported for 50 patients who underwent TFOI who were followed for the same time (10.2 points)<sup>34</sup>. This may indicate that the "ceiling for improvement" for transtibial amputation is not as low as some may think. In fact, 5 of our patients subjectively reported that the osseointegrated leg became their better leg.

The primary limitation of this study was the small cohort: 6 patients. Furthermore, there were multiple differences among the patients. Three patients were long-term amputees, while 3 had primary amputation with simultaneous osseointegration. There was also variation in specific dysvascular etiologies, age, comorbidities, and potentially other likely

relevant factors, such as employment and depression status, that were not evaluated. A relative strength of this study is that all patients were prospectively followed 3 to 5 years or until death. In vascular amputee literature, the follow-up time is often 1 year following primary amputation<sup>12-14</sup>, and for orthopaedic surgery, the consensus usually is 2 years. Follow-up for our patients exceeded those standards.

### Conclusions

Vascular pathology requiring transtibial amputation is not an absolute contraindication to osseointegration. Our series was small, and our study was not designed to evaluate potential survival benefits. While some patients experienced infection requiring antibiotics or operative debridement, they as well as the patients with uneventful courses improved with respect to mobility. Conscientious patient selection is important as osseointegration for this amputee cohort is explored. ■

Muhammad Adeel Akhtar, BSc, MBBS, MRCSEd, Dip SEM(UK), MD(Res), MFSEM, MFSTEd, PGDipCAOS, FEBOT, FRCSEd(T&O)<sup>1,2,3,4,5</sup>

Jason Shih Hoellwarth, MD<sup>5</sup>

Shakib Al-Jawazneh, MD<sup>5</sup>

William Lu, PhD<sup>6</sup>

Claudia Roberts, BPhysio(Hons)<sup>2,5</sup>

Munjed Al Muderis, MB, ChB, FRACS, FAOrthA<sup>2,4,7</sup>

<sup>1</sup>Trauma and Orthopaedic Department, Victoria Hospital Kirkcaldy, NHS Fife, Kirkcaldy, Scotland, United Kingdom

<sup>2</sup>Norwest Private Hospital, Bella Vista, New South Wales, Australia

<sup>3</sup>University of Edinburgh, Edinburgh, Scotland, United Kingdom

<sup>4</sup>University of St Andrews, St. Andrews, Scotland, United Kingdom

<sup>5</sup>Australian School of Advanced Medicine, Macquarie University, North Ryde, New South Wales, Australia

<sup>6</sup>Biomaterials and Tissue Engineering Research Unit, School of AMME, University of Sydney, Sydney, New South Wales, Australia

<sup>7</sup>School of Medicine, The University of Notre Dame Australia, Auburn, New South Wales, Australia

Email address for M.A. Akhtar: Adeel.akhtar@nhs.scot

### References

- Ziegler-Graham K, MacKenzie EJ, Ephraim PL, Travison TG, Brookmeyer R. Estimating the prevalence of limb loss in the United States: 2005 to 2050. *Arch Phys Med Rehabil*. 2008 Mar;89(3):422-9.
- Dillingham TR, Pezzini LE, MacKenzie EJ. Limb amputation and limb deficiency: epidemiology and recent trends in the United States. *South Med J*. 2002 Aug;95(8):875-83.
- Criqui MH. Peripheral arterial disease—epidemiological aspects. *Vasc Med*. 2001;6(3)(Suppl):3-7.
- Lazzarini PA, O'Rourke SR, Russell AW, Clark D, Kuys SS. What are the key conditions associated with lower limb amputations in a major Australian teaching hospital? *J Foot Ankle Res*. 2012 May 30;5(1):12.
- Kennedy G, McGarry K, Bradley G, Harkin DW. All-cause mortality amongst patients undergoing above and below knee amputation in a regional vascular centre within 2014-2015. *Ulster Med J*. 2019 Jan;88(1):30-5. Epub 2019 Jan 22.
- Scott SWM, Bowry S, Clarke D, Choke E, Bown MJ, Thompson JP. Factors influencing short- and long-term mortality after lower limb amputation. *Anaesthesia*. 2014 Mar;69(3):249-58.
- Soga Y, Iida O, Takahara M, Hirano K, Suzuki K, Kawasaki D, Miyashita Y, Tsuchiya T. Two-year life expectancy in patients with critical limb ischemia. *JACC Cardiovasc Interv*. 2014 Dec;7(12):1444-9.

8. Nelson MT, Greenblatt DY, Soma G, Rajimanickam V, Greenberg CC, Kent KC. Preoperative factors predict mortality after major lower-extremity amputation. *Surgery*. 2012 Oct;152(4):685-94; discussion 694-6.
9. Klaphake S, de Leur K, Mulder PG, Ho GH, de Groot HG, Veen EJ, Verhagen HJ, van der Laan L. Mortality after major amputation in elderly patients with critical limb ischemia. *Clin Interv Aging*. 2017 Nov 22;12:1985-92.
10. Stern JR, Wong CK, Yerovinkina M, Spindler SJ, See AS, Panjaki S, Loven SL, D'Andrea RF Jr, Nowygrod R. A meta-analysis of long-term mortality and associated risk factors following lower extremity amputation. *Ann Vasc Surg*. 2017 Jul;42:322-7. Epub 2017 Apr 5.
11. De Klerk C, Du Plessis G, Fourie JJ, O'Neill A, Smit SJA, Joubert G. The eventual outcome of patients who had lower limb amputations due to peripheral vascular disease at Pelonomi Hospital, Bloemfontein. *S Afr Fam Pract*. 2017;59(1):18-21.
12. Jones WS, Patel MR, Dai D, Vemulapalli S, Subherwal S, Stafford J, Peterson ED. High mortality risks after major lower extremity amputation in Medicare patients with peripheral artery disease. *Am Heart J*. 2013 May;165(5):809-15. Epub 2013 Feb 5.
13. Shah SK, Bena JF, Allemang MT, Kelso R, Clair DG, Vargas L, Kashyap VS. Lower extremity amputations: factors associated with mortality or contralateral amputation. *Vasc Endovascular Surg*. 2013 Nov;47(8):608-13. Epub 2013 Sep 4.
14. Dillingham TR, Pezzin LE. Rehabilitation setting and associated mortality and medical stability among persons with amputations. *Arch Phys Med Rehabil*. 2008 Jun;89(6):1038-45.
15. Stewart CP, Jain AS. Cause of death of lower limb amputees. *Prosthet Orthot Int*. 1992 Aug;16(2):129-32.
16. Turner AP, Meites TM, Williams RM, Henderson AW, Norvell DC, Hakimi KN, Czerniecki JM. Suicidal ideation among individuals with dysvascular lower extremity amputation. *Arch Phys Med Rehabil*. 2015 Aug;96(8):1404-10. Epub 2015 Apr 14.
17. Suckow BD, Goodney PP, Nolan BW, Veeraswamy RK, Gallagher P, Cronenwett JL, Kraiss LW. Domains that determine quality of life in vascular amputees. *Ann Vasc Surg*. 2015;29(4):722-30. Epub 2015 Feb 26.
18. Brånemark R, Brånemark PI, Rydevik B, Myers RR. Osseointegration in skeletal reconstruction and rehabilitation: a review. *J Rehabil Res Dev*. 2001 Mar-Apr;38(2):175-81.
19. Aschoff HH, Kennon RE, Keggi JM, Rubin LE. Transcutaneous, distal femoral, intramedullary attachment for above-the-knee prostheses: an endo-exo device. *J Bone Joint Surg Am*. 2010 Dec;92(Suppl 2):180-6.
20. Webster JB, Bachus KN, Beck JP, Jeyapalina S, Drew AJ, Bloebaum RD. Osseointegration research. In: Tepe V, Peterson CM, editors. Full stride. Advancing the state of the art in lower extremity gait systems. Springer Science and Business Media; 2017. p 167-93. [Ebook].
21. Gerzina C, Potter E, Haleem AM, Dabash S. The future of the amputees with osseointegration: a systematic review of literature. *J Clin Orthop Trauma*. 2020 Feb;11(Suppl 1):S142-8. Epub 2019 May 31.
22. Kunutsor SK, Gillatt D, Blom AW. Systematic review of the safety and efficacy of osseointegration prosthesis after limb amputation. *Br J Surg*. 2018 Dec;105(13):1731-41. Epub 2018 Oct 11.
23. Hebert JS, Rehani M, Stiegelmar R. Osseointegration for lower-limb amputation: a systematic review of clinical outcomes. *JBJS Rev*. 2017 Oct;5(10):e10.
24. Leijendekkers RA, van Hinte G, Frölke JP, van de Meent H, Nijhuis-van der Sanden MWG, Staal JB. Comparison of bone-anchored prostheses and socket prostheses for patients with a lower extremity amputation: a systematic review. *Disabil Rehabil*. 2017 Jun;39(11):1045-58. Epub 2016 Aug 5.
25. Brånemark RP, Hagberg K, Kulbacka-Ortiz K, Berlin Ö, Rydevik B. Osseointegrated percutaneous prosthetic system for the treatment of patients with transfemoral amputation: a prospective five-year follow-up of patient-reported outcomes and complications. *J Am Acad Orthop Surg*. 2019 Aug 15;27(16):e743-51.
26. Van de Meent H, Hopman MT, Frölke JP. Walking ability and quality of life in subjects with transfemoral amputation: a comparison of osseointegration with socket prostheses. *Arch Phys Med Rehabil*. 2013 Nov;94(11):2174-8. Epub 2013 Jun 14.
27. Brånemark R, Berlin Ö, Hagberg K, Bergh P, Gunterberg B, Rydevik B. A novel osseointegrated percutaneous prosthetic system for the treatment of patients with transfemoral amputation: a prospective study of 51 patients. *Bone Joint J*. 2014 Jan;96-B(1):106-13.
28. Hagberg K, Brånemark R, Gunterberg B, Rydevik B. Osseointegrated transfemoral amputation prostheses: prospective results of general and condition-specific quality of life in 18 patients at 2-year follow-up. *Prosthet Orthot Int*. 2008 Mar;32(1):29-41.
29. Hagberg K, Hansson E, Brånemark R. Outcome of percutaneous osseointegrated prostheses for patients with unilateral transfemoral amputation at two-year follow-up. *Arch Phys Med Rehabil*. 2014 Nov;95(11):2120-7. Epub 2014 Jul 24.
30. Al Muderis M, Khemka A, Lord SJ, Van de Meent H, Frölke JPM. Safety of osseointegrated implants for transfemoral amputees: a two-center prospective cohort study. *J Bone Joint Surg Am*. 2016 Jun 1;98(11):900-9.
31. Atallah R, Li JJ, Lu W, Leijendekkers R, Frölke JP, Al Muderis M. Osseointegrated transtibial implants in patients with peripheral vascular disease: a multicenter case series of 5 patients with 1-year follow-up. *J Bone Joint Surg Am*. 2017 Sep 20;99(18):1516-23.
32. Haque R, Al-Jawazneh S, Hoellwarth J, Akhtar MA, Doshi K, Tan YC, Lu WY, Roberts C, Al Muderis M. Osseointegrated reconstruction and rehabilitation of transtibial amputees: the Osseointegration Group of Australia surgical technique and protocol for a prospective cohort study. *BMJ Open*. 2020 Oct 20;10(10):e038346.
33. Al Muderis M, Lu W, Tetsworth K, Bosley B, Li JJ. Single-stage osseointegrated reconstruction and rehabilitation of lower limb amputees: the Osseointegration Group of Australia Accelerated Protocol-2 (OGAAP-2) for a prospective cohort study. *BMJ Open*. 2017 Mar 22;7(3):e013508.
34. Muderis MA, Tetsworth K, Khemka A, Wilmot S, Bosley B, Lord SJ, Glatt V. The Osseointegration Group of Australia Accelerated Protocol (OGAAP-1) for two-stage osseointegrated reconstruction of amputated limbs. *Bone Joint J*. 2016 Jul;98-B(7):952-60.
35. Leijendekkers RA, Staal JB, van Hinte G, Frölke JP, van de Meent H, Atsma F, Nijhuis-van der Sanden MW, Hoogeboom TJ. Long-term outcomes following lower extremity press-fit bone-anchored prosthesis surgery: a 5-year longitudinal study protocol. *BMC Musculoskelet Disord*. 2016 Nov 22;17(1):484.
36. Hagberg K, Brånemark R, Hägg Ö. Questionnaire for Persons with a Transfemoral Amputation (Q-TFA): initial validity and reliability of a new outcome measure. *J Rehabil Res Dev*. 2004 Sep;41(5):695-706.
37. Gailey RS, Roach KE, Applegate EB, Cho B, Cuniffe B, Licht S, Maguire M, Nash MS. The amputee mobility predictor: an instrument to assess determinants of the lower-limb amputee's ability to ambulate. *Arch Phys Med Rehabil*. 2002 May;83(5):613-27.
38. Lin SJ, Bose NH. Six-minute walk test in persons with transtibial amputation. *Arch Phys Med Rehabil*. 2008 Dec;89(12):2354-9. Epub 2008 Nov 1.
39. Schoppen T, Boonstra A, Groothoff JW, de Vries J, Göeken LNH, Eisma WH. The timed "up and go" test: reliability and validity in persons with unilateral lower limb amputation. *Arch Phys Med Rehabil*. 1999 Jul;80(7):825-8.
40. Sattelmair JR, Kurth T, Buring JE, Lee IM. Physical activity and risk of stroke in women. *Stroke*. 2010 Jun;41(6):1243-50. Epub 2010 Apr 6.
41. Manson JE, Hu FB, Rich-Edwards JW, Colditz GA, Stampfer MJ, Willett WC, Speizer FE, Hennekens CH. A prospective study of walking as compared with vigorous exercise in the prevention of coronary heart disease in women. *N Engl J Med*. 1999 Aug 26;341(9):650-8.
42. Sacco RL, Gan R, Boden-Albala B, Lin IF, Kargman DE, Hauser WA, Shea S, Paik MC. Leisure-time physical activity and ischemic stroke risk: the Northern Manhattan Stroke Study. *Stroke*. 1998 Feb;29(2):380-7.
43. Batty GD. Physical activity and coronary heart disease in older adults. A systematic review of epidemiological studies. *Eur J Public Health*. 2002 Sep;12(3):171-6.
44. Khemka A, Frossard L, Lord SJ, Bosley B, Al Muderis M. Osseointegrated total knee replacement connected to a lower limb prosthesis: 4 cases. *Acta Orthop*. 2015;86(6):740-4. Epub 2015 Aug 27.
45. Al Muderis M, Lu W, Li JJ. Osseointegrated Prosthetic Limb for the treatment of lower limb amputations: experience and outcomes. *Unfallchirurg*. 2017 Apr;120(4):306-11.
46. Juhnke DL, Aschoff HH. [Endo-exo prostheses following limb-amputation]. *Orthopade*. 2015 Jun;44(6):419-25. German.
47. Aschoff HH, Juhnke DL. [Endo-exo prostheses: osseointegrated percutaneously channelled implants for rehabilitation after limb amputation]. *Unfallchirurg*. 2016 May;119(5):421-7. German.
48. Hoffmeister T, Schwarze F, Aschoff HH. [The endo-exo prosthesis treatment concept: improvement in quality of life after limb amputation]. *Unfallchirurg*. 2017 May;120(5):371-7. German.
49. Leijendekkers RA, van Hinte G, Frölke JP, van de Meent H, Atsma F, Nijhuis-van der Sanden MW, Hoogeboom TJ. Functional performance and safety of bone-anchored prostheses in persons with a transfemoral or transtibial amputation: a prospective one-year follow-up cohort study. *Clin Rehabil*. 2019 Mar;33(3):450-64. Epub 2018 Dec 12.
50. Klute GK, Berge JS, Orendurff MS, Williams RM, Czerniecki JM. Prosthetic intervention effects on activity of lower-extremity amputees. *Arch Phys Med Rehabil*. 2006 May;87(5):717-22.
51. Hagberg E, Berlin ÖK, Renström P. Function after through-knee compared with below-knee and above-knee amputation. *Prosthet Orthot Int*. 1992 Dec;16(3):168-73.
52. Asano M, Rushton P, Miller WC, Deathe BA. Predictors of quality of life among individuals who have a lower limb amputation. *Prosthet Orthot Int*. 2008 Jun;32(2):231-43.